

PATIENT PRESENTING CLINICAL SIGNS

Bonk Harris History: Grade I-II/VI heart murmur; no clinical signs. Echocardiogram prior to anesthesia for dental prophyl. BP: 174,187, 188mmHg.

SPECIES ECHOCARDIOGRAM FINDINGS

Feline 2D, m-mode, color flow and Doppler imaging is available.

BREED

Persian

SEX

Male Neutered

AGE

9 years

WEIGHT

9.9lbs

Left ventricle: The LV diameter is normal with adequate myocardial function. The LV wall thicknesses are normal yet irregular. There is a diffusely hyperechoic endocardium consistent with fibrosis. The papillary muscles are remodeled and hyperechoic. The endocardium appears remodeled.

Left atrium: The left atrium is severely dilated with spontaneous contrast/smoke. No obvious thrombi. The auricle is also significantly dilated.

Mitral valve: The mitral valve is normal in structure and mobility. No obvious systolic anterior motion is seen. Trace central MR due to annular stretch.

Aortic valve/Aorta: The aortic valve is normal in morphology and mobility. Normal aortic outflow velocity; laminar flow. No aortic insufficiency.

Right ventricle: The RV appears largely normal.

Right atrium: The right atrium is normal.

Tricuspid valve: The tricuspid valve appears normal with no tricuspid regurgitation.

Pulmonic valve/Pulmonary artery: The pulmonic valve is normal in morphology and mobility. Trace pulmonic insufficiency. Normal RVOT velocity; laminar flow.

Pericardium/other: No pericardial or pleural effusion noted. No obvious cardiac masses.

Heart rhythm: ECG reveals a sinus rhythm with an average HR of 220bpm.

INTERPRETED BY

Maggie Machen
Lamy, DVM
DACVIM (Cardiology)

2-Dimensional Measurements

Ao diam (cm)	0.9
LA diam (cm)	2.0
LA:Ao (Swe)	2.4
IVS thickness (cm)	0.53
LVID diastole (cm)	1.2
PW thickness (cm)	0.48
LVID systole (cm)	0.7
FS (%)	43

Doppler Measurements

PV Vmax (m/s)	1.1
AoV Vmax (m/s)	0.8
MR Vmax (m/s)	NA
TR Vmax (m/s)	NA
TR PG (mmHg)	NA

IMAGING

PERFORMED BY

Pamela Harrigan,
RDMS

INTERPRETATION OF THE FINDINGS

HOSPITAL NAME

Wignall Animal
Hospital

The finding of severe left atrial enlargement in the face of normal LV wall thickness and is most consistent with Unclassified Cardiomyopathy (UCM), however burn-out or end-stage HCM can also have this appearance. Severe left atrial dilation is present, which indicates high risk for decompensation. There is also significant LV remodeling and fibrosis which indicates severe diastolic dysfunction. No additional issues are identified.

REFERRING VET

Dr. Thomas

Regardless of categorical classification, this degree of atrial dilation confers high risk for spontaneous congestive heart failure in the near future and **lifelong medications are warranted as below even without reported clinical signs.**

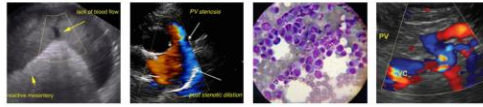
INVOICE

23502

DATE

4/7/22

The long-term prognosis is guarded to poor even with medications; however, most cats are able to maintain a good quality of life for some time. There will always remain risk for progression to CHF and development of additional blood clots in the future.



PATIENT

Bonk Harris

SPECIES

Feline

BREED

Persian

SEX

Male Neutered

AGE

9 years

WEIGHT

9.9lbs

INTERPRETED BY

Maggie Machen
 Lamy, DVM
 DACVIM (Cardiology)

IMAGING PERFORMED BY

Pamela Harrigan,
 RDCS

HOSPITAL NAME

Wignall Animal
 Hospital

REFERRING VET

Dr. Thomas

INVOICE

23502

DATE

4/7/22

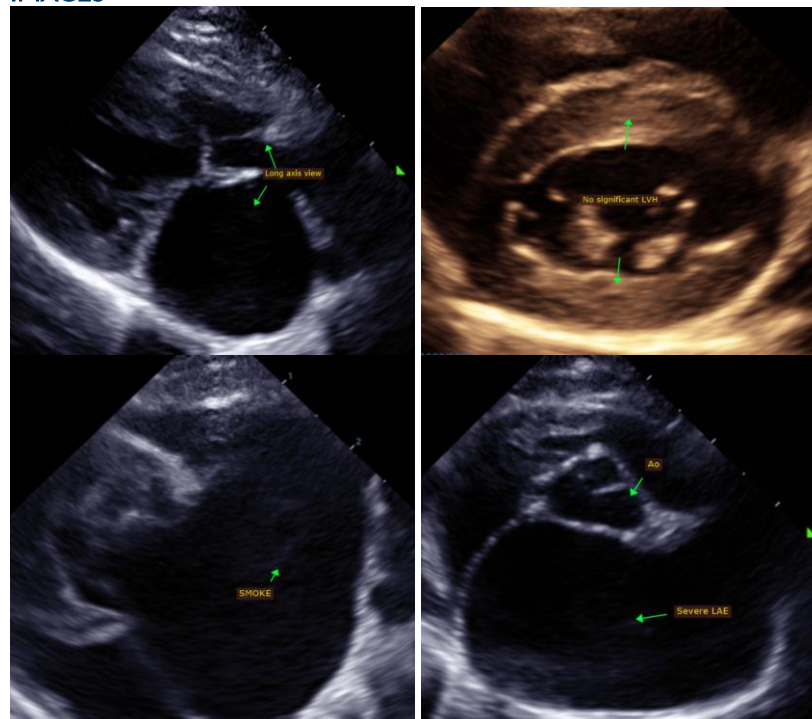
RECOMMENDATIONS

- Institute low dose Lasix/furosemide 1mg/kg PO q12h.
- Institute blood thinner Clopidogrel (Plavix) 75mg tablets; give ¼ tab orally once daily (NOTE: this medication is very bitter on the cut edges).
- Institute Pimobendan (off label use) 1.25mg PO q12h.
- **Elective anesthesia, fluid or steroid therapy is not advised.**
- Monitor for any clinical evidence of cardiac compromise, including respiratory changes and/or signs of a blood clot event (paralysis, neurologic changes, etc.).

PLAN

- Recheck renal panel, and BP in 1-2, then every 4-6 months lifelong. If doing well and BP is >130mmHg (and patient is able to be easily medicated), institute ACEI 0.5mg/kg PO q12h.
- Recheck echocardiogram in 6 months, sooner if clinical signs arise.

IMAGES



The information and recommendations provided are based on the images presented by the referring veterinarian. No evaluation can be communicated regarding pathology that was not visible in the image/video clips provided.

Thank you for this referral. This report was generated using transcription software, and minor dictation errors may be present. If the clinical or image interpretation does not parallel your findings or if I can be of any further assistance, please contact me.

Maggie Machen Lamy, DVM
 Diplomat of the American College of Veterinary Internal Medicine (Cardiology)
 info@sonopath.com